Goiters in the Renaissance

F. G. Vescia and L. Basso

Summary

Enlargements of the thyroid gland known as goiters appear in artworks and artifacts of many cultures. They are represented in sculptures, bas-reliefs, masks, waxes, mosaics, bronzes, stained glass windows, paintings and drawings of the last two millennia. These are described in several monographs and in Merke's scholarly History and Iconography of Endemic Goitre and Cretinism (Barbieri 1993, Gianpalmo and Fulcheri 1988, Gianpalmo 1992, Medvei 1982, Merke 1984). Most numerous among these works are the portrayals of goiters in paintings and drawings of the Renaissance. This essay lists eleven additional Renaissance artworks in which goiters are represented, as well as reviewing reasons for this occurrence and examines the unusual case of Piero della Francesca.

Résumé

L'augmentation de volume de la glande thyroide, appelée goître, apparaît dans l'art de nombreuses cultures. On les trouve dans les sculptures, bas-reliefs, cires, bronzes, vitraux, peintures et dessins des deux derniers millénaires. Ils ont été décrits dans plusieurs monographies ainsi que dans l'Histoire et Iconographie du Goître Endémique et du Crétinisme de Merke (Barbieri 1993, Gianpalmo and Fulcheri 1988, Gianpalmo 1992, Medvei 1982, Merke 1984). Souvent ces goîtres apparaissent dans la peinture et les dessins de la Renaissance. Cet article mentionne onze exemples peints ou dessinés pendant cette période, il aborde la cause de leur survenue et s'interroge sur le cas insolite de Piero délia Francesca.

Goiters in History

Over the centuries, physicians have viewed goiters differently. (Medvei 1982 45,72,86,109, 116, 11,159)Inthe5thcentury BC,Hippocrates thought they were deformities of the cervical glands caused by drinking snow water. In 85 AD, the Chinese physician Tshui Chih-Thi distinguished between solid and soft goiters, recognizing the first as incurable, the latter as Deni9n-

Fernando G. Vescia, M.D., 1629 Edgewood Dr., Palo Alto, CA 94303, U.S.A.

Lawrence Basso, M.D., c/o P.A.M.F., 300 Homer Ave. Palo Alto, CA 94301, U.S.A.

|nthesecondcentury AD, Galen referred to goiters as bronchoceles, bronchial dilatations. TheGreek physician of the Byzantine period, Pau|of Aegina (625·69o AD), contrasted them wjth aneurysma| dilatations and called them steatomata or fatty swellings,

Scholars of the school of Salerno used the term botium for bronchoce|e· Guttur tumidum, the popular appelation for goiters, became gozzo in Italian, goitre in French and kropf or struma in German. In the 14th century, Arnold of Villanova (1235-1311) found goiters responded best to a combination of sponge and seaweed, while a surgeon at Montpellier, Guy de Chauliac (1 300-1 370) recommended surgical extirpation. Paracelsus (1493-1541) compared

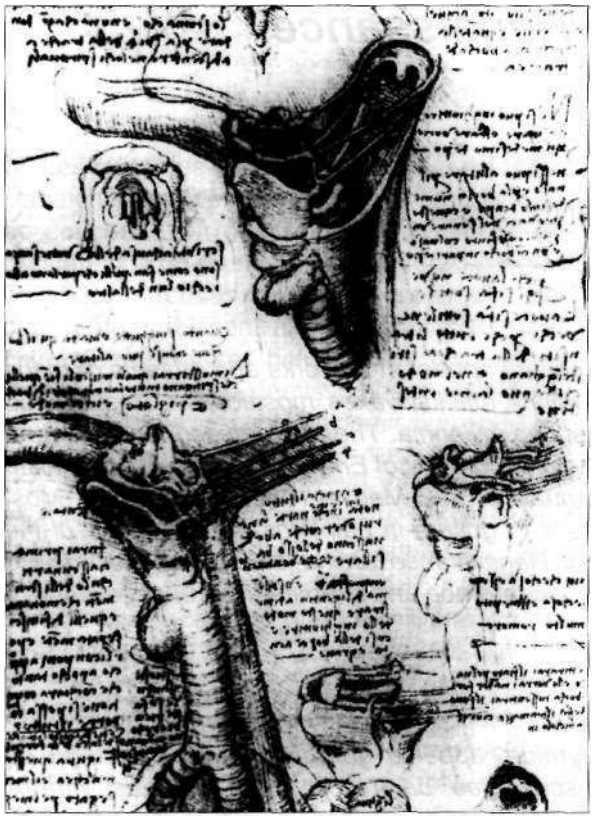

• *Fig. 1 First drawing of the thyroid (Leornardo da Vinci)*

goiters to the burls of trees and believed they were produced by the irritation of minerals in the water. (Paracelsus 1603 174-182)

These were merely speculations since anatomical studies had ceased at the end of the Hellenistic period. The influx of Greek refugees in Italy at the beginning of the Renaissance restored an interest in antiquity. Greek and Roman texts were re-introduced and anatomical dissections resumed. Until then, artists depicted mainly religious themes : the Virgin and Child, the Passion of Christ, the Resurrection and the Lives of Saints. Having solved the problem of perspective, the artists of the Renaissance were expanding their themes and providing accurate representations of the world around them.

Physicians performing anatomies were often joined by artists eager to learn about the musculature of the human body. Among those participating in these activities were the artists Antonio Pollaiuolo, Luca Signorelli, Leonardo da Vinci, Michelangelo Buonarroti, and Sandro Botticelli.

The thyroid as such was as yet unknown. The first drawing of the organ (fig. 1) drawn in 1510, was a sketch by the Florentine artist Leonardo da Vinci (O'Malley & Saunders 1952 387). Leonardo's sketch was part of a series of anatomical studies he was conducting at the hospital of Santa Maria Nuova in Florence. Two centuries laterthe British anatomist John Hunter marveled at the precision and artistic qualities of these drawings. Unaware of the role of the thyroid, Leonardo wrote in the margin of his sketch: 'These glands are made to fill the interval where the muscles are lacking and hold the trachea away from the sternal notch (forcula)'. (O'Malley and Saunders 1952 386).

Unfortunately, Leonardo's drawings and notebooks disappeared after his death in 1519 and did not resurface until the 18th century. Thus, it was not until the publication of Vesalius' De Humani Corporis Fabrica in 1543 that the thyroid gland became known to physicians. Vesalius' study was technically and artistically inferior to Leonardo's sketch as is clear when one compares the two illustrations (fig. 1 and 2.) The one in the Fabrica was drawn after the thyroid of a domestic animal, (fig. 2) on the incorrect assumption that the human thyroid is similar to that of other species. It was, also, poorly detailed . (O'Malley & Saunders 1952 386).

Bartolomeo Eustachius (1520-1574), one of Vesalius'contemporaries, referred to the thyroid as glandula laryngis, (Merke 1984 180) and Boehelius, another anatomist, assumed it was intended to moisten the trachea and lungs (Medvei 1982 109). A century later, Richard Wiseman, (1622-1676) surgeon to the English monarch Charles 11, believed goiters were caused by scrofula, the King's Evil (tuberculous adenitis). (Medvei 1982 136).

In 1656, Thomas Wharton published a monograph on the glands of the body in which he first used the term glandulae thyroideae. His

Fig.2 Drawing of the thyroid gland, in De Humani Corporis Fabrica

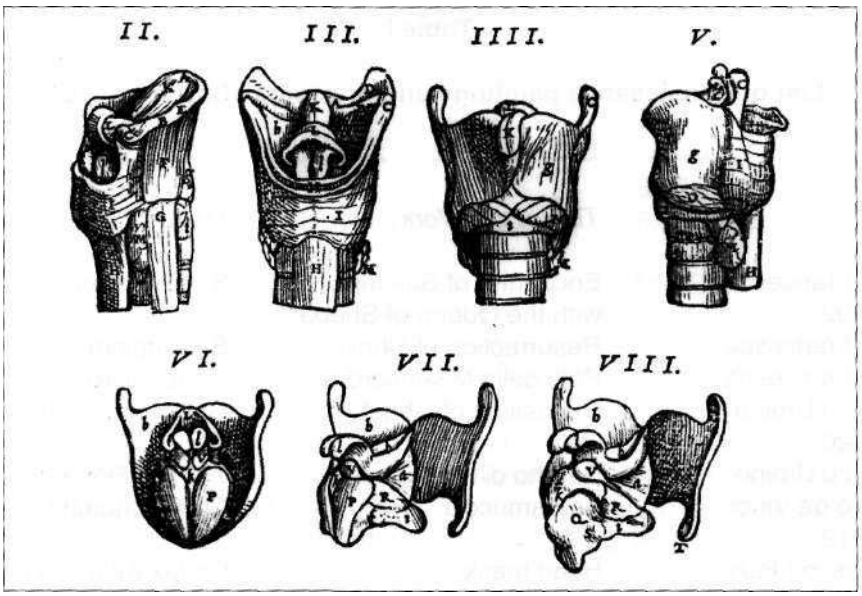

appellation was based on the thyroid's proximity to a cartilage in the neck resembling a shield, *or* thyreos in Greek. Albrecht von Haller (1708-1777,) was the first to realize goiters were enlargements of the thyroid gland, but he offered no explanation for the hypertrophy. (Merke 1984 190).

It was not until a hundred years later, that Gaspard Adolphe Chatin, a gifted botanist and pharmacist working at the Hotel Dieu in Paris, suggested that' too little iodine in the drinking water might well be the principal cause of goiter' (Merke 1984 12) and advised using iodine-rich products to treat them.(Sawin 1995 165-168). The deficiency of iodine was caused by the melting of glaciers, at the end of the quaternary with the leaching of iodine from the soil (Merke 1984 29-45). After some false starts, because of excessive dosages, the addition of iodine proved therapeutic. Goiters began to shrink and became less frequent. Until the 19th century, they had been common in Switzerland, the Valais and in Alpine communities (Merke 1984 225) hence their inclusion in a variety of artworks.

Goiters in paintings and drawings

It comes as no surprise that representations of goiters appear predominantly in paintings and drawings, these being the two most common forms of artistic expression. A search for artworks portraying goiters revealed them to be particularly plentiful during the Renaissance, yielding a list of 56 such works.

What motivated artists to wish to paint goiters? Like their predecessors, artists of the Renaissance favored beautiful features and ignored or minimized physical defects. Goiters were included in their paintings as the result of several circumstances. Artists like Mantegna, Masaccio, Piero della Francesca and others had solved the problem of perspective and were able to represent what they saw, 'as the eye sees it'. Some artists, like Leonardo da Vinci, were actually fascinated by strange physiognomies. Leonardo's drawing of Scaramuccia a soldier of fortune, with a large nodular goiter, (fig. 3) is an example. Goiters were relatively common in various Alpine localities where artists depicted what they saw. Eventually, others must have wanted to imitate them and include goiters in their paintings and drawings, hence their presence in artworks of the Renaissance.

The list of paintings and drawings in which goiters are represented, offered in Table I , is necessarily incomplete. More works must have been produced than we were able to find. Many were probably lost.

Table I identifies these works by their titles, locations, names and the artists' dates.

Table I

List of Renaissance paintings and drawings showing goiters

	Artist	*Title of the Work*	*Location*
1.	P. della Francesca 1410-1492	Encounter of Solomon with the Queen of Sheba	S. Francesco, Arezzo
2.	P. della Francesca	Resurrection of Christ	S. Sepolcro
3.	P. della Francesca	Pala della Misericordia	S. Sepolcro
4.	Raffaello d'Urbino 1483-1520	Deposition of Christ	G. Borghese, Rome
5.	Raffaello d'Urbino	Ritratto di F. Inghirami	? Uffizi, Florence
6.	Leonardo da Vinci 1452-1519	Scaramuccia	Christ Church Lib., Oxford
7.	? Francesco Melzi 1491-1570	Head mask	Codex Atlanticus, Milan
8.	Michelangelo B. 1475-1564	self-portrait	Florence *
9.	Sandro Botticelli 1444-1510	Ritratto di donna	Pitti Palace, Florence
10.	Pinturicchio 1454-1513	Myth of Isis and Osiris	Vatican Museum, Rome **
11.	Sch. of Pinturicchio	Bacchic scene	Uffizi, Florence
12.	Bramantino 1460-1530	Adoration of the child	Ambrosiana, Milan
13.	Bramantino	Pieta	Castello Sforzesco, Milan
14.	? Bramantino	Tapestry for Trivulzio	Uffizi, Florence
15.	?	Bergamask woman (1557)	Metropolitan Museum N.Y.
16.	Jacopo da Valencia active 1488-1519	Resurrection of Christ	Verona
17.	Vincenzo Foppa 1427-1515	The Visitation	Brera, Milan
18.	Vincenzo Foppa	St. Bonaventura	Castello Sforzesco, Milan
19.	Vincenzo Foppa	St. Sebastian	Castello Sforzesco, Milan
20.	Marino Spanzotti 1456-1526	L'infemo	Ivrea
21.	Masaccio 1401-1428	St. Peter healing the sick	Brancacci Chapel, Florence
22.	Gaudenzio Ferrari 1471-1546	Adoration of the Magi	S. Cristoforo, Vercelli
23.	Gaudenzio Ferrari	Life of St. Lawrence	S. Monte d'Orta
24.	Unknown artist	Altarpiece	Pal. Muratori, Savigliano
25.	Dosso Dossi 1490-1542	Apollo	Gall. Borghese, Rome
26.	Unknown artist	Martydom of St. ?	S. Giulio d'Orta
27.	Lorenzo di Pietro active 1437-1470	Altarpiece	Siena Art Gallery
28.	Pietro di Saluzzo ?	Woman among sinners	Costanzo, Cuneo

29.	G. Mazzucco ?	Altarpiece	S. Fiorenzo, Cuneo
30.	Tabacchetti -1577 (J. Wespin)	? Martyrdom of Christ	S. Monte di Varallo, Val di Sesia
31.	Il Sodoma 1477-1549	Bricklayer, Life of St. Benedict	Mte Oiiveto Maggiore
32.	Il Sodoma	Farmer, Life of St. Benedict	Mte Oiiveto Maggiore
33.	Giacomo Jacquerio	Stable Boy	Saluzzo
34.	Unknown artist	Arrest of Jesus	Stura, Cuneo
35.	Unknown artist	Martyrdom of St. Sebastian	S. Domenico in Alba, Cuneo
36.	Unknown artist	Martyrdom of St. Agatha	S. Domenico, Savona
37.	Unknown artist	? altarpiece	Cathedral in Aosta
38.	Il Moretto 1498-54 Aless. Benvicino	? The nativity	Art Gall., Brescia
39.	Unknown artist	Pharmacy Boy	The Prado, Madrid
40.	Roger Van der Weyden 1399-1464	Virgin & Child	Val d'Aosta
41.	Unknown artist	The flagellation	Duomo di Chieri
42.	Il Morazzone 1573-1626 (P.F. Mazzucchelli)	Ascent to Calvary	S. Monte di Varallo
43.	Il Morazzone	St. Roch	Castello Sforzesco, Milan
44.	HCeranino?- 1675 (Melchiore Gherardini)	?	S. Monte di Varallo
45.	Unknown artist	Last Supper	San Martino di Dito, Switz
46.	Dionigi Bussola ? 1627-87	Crucifixion	Varese
47.	Jusepe Ribera 1588-1656	Caricature of a man	The Uffizi, Florence
48.	Jusepe Ribera	Man with goiter ****	Wellcome Inst., London
49.	Hans Holbein	Eve tempting Adam	Kunstmuseum, Basel
50.	Hans Holbein	Scourging of Christ	Offentliche Kunst., Basel
51.	HCerano 1576-1633 (Giovan Battista Crespi)	S. Francesco in estasi	Brera, Milan
52.	Giulio C. Procaccini 1574-1625	Giuditta e Oloferne	Castello Sforzesco, Milan
53.	Giovanni M. Udine 1487-1561/64	S. Orsola tra le vergini	Castello Sforzesco, Milan
54.	Albrecht Durer 1471-1528	The desperate man *****	Petit Palais, Paris
55.	Albrecht Durer	The doctor's dream ****	Petit Palais, Paris
56.	Albrecht Durer	Ulrich Varnbuler ****	Petit Palais, Paris

* Florence, Archivio Buonarroti, XIII, fol. III
** Borgia Apartments
*** Tapestry for Gian Giacomo Trivulzio
**** Engravings
*****Etching

Fig.3 Drawing of Scaramuccia by Leonardo da Vinci

Some of the listings in Table I are incomplete, their attributions being uncertain or the dates of the works unknown. They are included because of the similarity of their style and content to works of the Renaissance depicting goiters. Three items (44, 47 and 48) which belong to the Mannerism period, which follows the Renaissance, are likewise included being in the same tradition as the works in the rest of the series.

A review of the artworks listed in Table I reveals four types of goiters:

1. Pseudo-goiters, in subjects with prominent Adam's apples, as in the painting of The Rock byMazzuchello, in the Pinacoteca of the Castello Sforzesco in Milan.

2. Imaginary goiters perceived by the artists, but not really present. A good example may be observed in a self-sketch by Michelangelo. In the margin, Michelangelo wrote:' I have developed a goiter for my efforts'. (fig.4) (Merke 1984154). At the time, he was working long hours on a scaffolding with his neck hyperextended, painting the ceiling of the Sistine Chapel. He was 39 years old. His biographer, Giorgio Vasari, does not mention Michelangelo's goiter nor is one visible in the artist's other portraits.

Eleven of the works listed above (18,19,43, 49, 50, 50-56) have not figured in previous publications. Durer's engraving of The Desperate Man (item 54) is an allegory of a man (Durer used his brother Enders as a model) surrounded by four figures representing the four humors. The sanguine humor, which dominates the other three figures, shows a man with a florid goiter. One could argue that Durer was as yet inexperienced with acid etching, contrasted with wood or copper engravings, and that the lines around the neck indicating a goiter were accidental, though this would be hard to explain in an artist considered the master engraver of all time.

Michelangelo lived fifty more years without signs or symptoms of thyroid disease. What he assumed was a goiter was probably a sore neck caused by cervical radiculitis.

In a poem (Sonnet V) which accompanies the drawing, Michelangelo provided another interesting detail. He compared himself to 'cats which develop goiters from the waters of

Fig.4 Self-sketch by Michelangelo showing "alleged goiter"

Lombardy'. (Merke 1984 154). In addition to expressing a popular belief, his poem reveals that domestic felines were as prone to goiters as the inhabitants of the region. Deer, by contrast, were spared, their habitat extending beyond the iodine-poor belt.

3. 'Allegorical goiters' used by artists to identify devils and vicious characters such as torturers and henchmen. There are numerous examples of this type of goiter. One can be seen in Francesco Melzi's Head Mask (item 7), patterned after a lost drawing of Leonardo da Vinci. Others can be seen in Holbein's The scourging of Christ, (item 50,) and the Martyrdom of St Agatha (item 36) in the church of San Domenico in Savona.

A fresco of The Last Supper, showing Judas with an 'allegorical goiter' is in the chapel of San Martino di Dito, Ticino, Switzerland (item 45). In addition to having a goiter, Judas is portrayed as a myxedematous cretin (fig.5). The artist was unaware of the contradiction he had portrayed as'cretins', at the time were considered innocent and incapable of sinning. (Merke 1984 291).

Another remarkable example of an allegorical goiter appears in Holbein's portrait of Eve tempting Adam. Eve is shown holding an apple, the quintessential symbol of temptation. (fig. 6). In addition to having a goiter Eve appears distinctly myxedematous, a clue as to how Holbein viewed the original sinner. Or was the association strictly fortuitous ?

4. This leaves real goiters, which artists included because they were really present, as in Ribera's Man with goiter in the Wellcome Collection (item 48) and in Leonardo's Scaramuccia. (item 6).

The three paintings of Piero Francesca (items 1, 2 and 3) listed in Table I, are especially challenging. Like many artists before and after him, Piero included himself in his works. In the first painting completed in 1455-56, entitled The Encounter of Solomon with the Queen of Sheba, Piero is in the second row, wearing a black cap. His goiter, partly obscured by the collar, is less distinct than in the next two paintings.

In the second painting, finished in 1458, entitled The Resurrection of Christ, (fig. 7) Piero

Fig. 5 Detail from the painting of The Last Supper in the Chapel of Dito, Switerzerland

is the Roman soldier leaning against Jesus' grave. His face is drawn, his eyelids shut, his eyes slightly bulging, his eyebrows full. A round, smooth swelling in the middle of the neck extends to the inner border of the left sternocleidomastoid.

The same lemon-size mass appears in Piero's third self-portrait in the Pala della Misericordia, (figure 8) finished between 1460-62. Here, Piero is the second man from the right, under the mantle of the Virgin Mary. He was 40 at the time. We know from Vasari's description, in his Lives of the Famous Painters, (Vasari 193 331) that Piero stopped working at 56 because he was going blind. This was sixteen years before his death at 72. Vasari added that Piero suffered from a tremor of his hands.

Can one arrive at a diagnosis based on these observations? If the swelling was an autonomous overactive nodule, so called 'toxic nodule', this would have accounted for Piero's tremor, but not for his eye problems. If Piero suffered from Graves' disease, he should have had exophthalmos and the typical 'stare'. If, on the other hand, Piero' s goiter were malignant, he might have died sooner, although malignant thyroid neoplasms may be slow growing.

A more likely possibility, according to the Italian surgeon, Andrea Trenti (Trenti 1992 19) is that of a benign thyroglossal cyst. In that case, Piero's blindness, his tremor late in life and ultimately his demise (Trenti 1992 32) would have been unrelated. Piero's presumed remains were exhumed in 1956. They could not be studied, hence they offered no clues as to the nature of the swelling.

Goiters in Medicine

Most of the goiters listed in Table I are large goiters, typical of iodine deficiency. They are either diffuse or nodular. It is reasonable to assume they are a fair representation of the goiters of the time. The majority of to-day's goiters, by contrast, are smaller, resulting from auto-immune disorders such as Graves' disease and Hashimoto's thyroiditis. That these were not featured in the paintings and drawings of the Renaissance suggests that G raves' disease may not have existed as we know it today or escaped the attention of the artists, two equally puzzling alternatives.

Fig. 6 Detail from the painting of Eve tempting Adam by Hans Holbein

If it is true, as somebody stated, that genius is the capacity to take infinite pains, then artists of the Renaissance who were as interested in abnormal physiognomies as Leonardo da Vinci could not have failed to document the stigmata of Graves' disease.

Conclusion

It is interesting to note that almost all of the theories offered through the centuries concerning the pathogenesis of goiters contained a kernel of truth. What can we conclude from reviewing these artworks ? The documentation of goiters by the artists of the Renaissance provides a unique historical record. A simple inspection reveals how more accurate these paintings and drawings are than those of previous eras.

Therapeutic advances introduced in the last hundred years have made iodine deficient goiters a rare occurrence in the West, though they are still prevalent in different pockets of the Third World. Thus, in a sense, these paintings and drawings offer a selective medical vision of the past.

They are interesting in addition, not only for what they show, but for what they fail to show, i.e. the apparent absence of Graves' disease and Hashimoto's thyroiditis. If these are recent conditions, what could account for their emergence ? Could this be due to seaweed added to foods and fertilizers with their additional dietetic load of iodine ? Could other dietary changes, unsuspected infections, mutations, or the interaction of unsuspected factors play a role in this process ? Nobody knows for sure. Until we do, these paintings and drawings of the Renaissance will remain an important documentation of the past.

• Fig. 7 Detail from The Resurrection of Christ by Piero delta Francesca

References

Barbieri L.L. (1993) Esempi di patologia tiroidea nell'arte. Minerva Medica; 84 : 151-154.

Giampalmo A. and Fulcheri E. (1988) An investigation of endemic goiter during the centuries in sacral figurative arts. Zentralblatt allgemeine patholog. Anatomie 134 : 297-307.

Giampalmo A. (1992) Testimonianza di Patologia nella storia delle arti figurative. Pathologica; 84:1 -24.

Medvei V.C. (1982) A History of Endocrinology. MTP Press, Hingham, MA. 11, 45, 72, 86, 109, 116, 136, 159.

Merke F. (1984) History and Iconography of Endemic Goitre and Cretinism. Hans Huber publishers, Berne, 12, 29-45, 154, 180, 190, 291.

O'Malley CD. and Saunders J.B. de CM. (1952) Leonardo da Vinci on the human body. Henry Schuman, N.Y. 386,387.

Paracelsus (Bombastus ab Hohenheim, A.P.T.) (1603) De Generatione Stultorum. Opera II, Strassburg; 174-182.

Sawin CT. (1995) Adolphe Chatin (1813-1901) Iodine in the Prevention of goiter. The Endocrinologist. vol.5 #3 : 165-168.

Trenti A. (1992) Indiscrezioni su Piero. Editrice Edigraph & Images s.r.l. Rome; 19, 32.

Vasari G. (1963) Lives of the Most Eminent Painters, Sculptors and Architects. Everyman's Library, N.Y. 331.

Biographies

Dr. Fernando G. Vescia is a lecturer in the History of Medicine at Stanford University Schoool of Medicine, Stanford, California. He is an emeritus clinical associate professor and the author of several articles in the History of Medicine and in Gastroenterology.

Dr. Lawrence Basso is an endocrinologist at the Palo Alto Medical Foundation in Palo Alto. California and a clinical professor of Medicine at Stanford University School of Medicine, Stanford, California. He is ***the*** *author of several articles and a book on immuno-assays.*

Fig. 8 Detail from Pala delta Misericordia by Piero delta Francesca